Working Title: Imaging of unfavorable intermediate risk prostate cancer has low yield and leads to unnecessary testing, procedures, and costs

Current Authorship: Angela Hacksel, M.D., Dhiren Shah, M.D., Shaan Mehta, Stephanie Cummings, Sebastian Caraballo, Kent Chevli, M.D.

## Introduction and Objectives

NCCN guidelines for Prostate Cancer (CaP) recommend all patients with unfavorable intermediate risk disease receive bone or soft tissue imaging. Guidelines cite Hopkins and Memorial Sloan Cancer Center nomograms as a component of the decision-making criteria; however, the Partin Tables combine Grade Group 3 and 4 into a single recommendation set. Overall imaging yield vs harm for unfavorable intermediate risk patients is debatable.

The current study seeks to evaluate if NM Bone scan or PSMA PET is necessary for unfavorable intermediate risk CaP. The primary outcome variable is confirmed finding on NM Bone scan or PSMA PET scan.

## Methods

We retrospectively identified 398 patients with primary unfavorable intermediate risk CaP who underwent either NM Bone Scan or PSMA PET between September 2021 and April 2023.

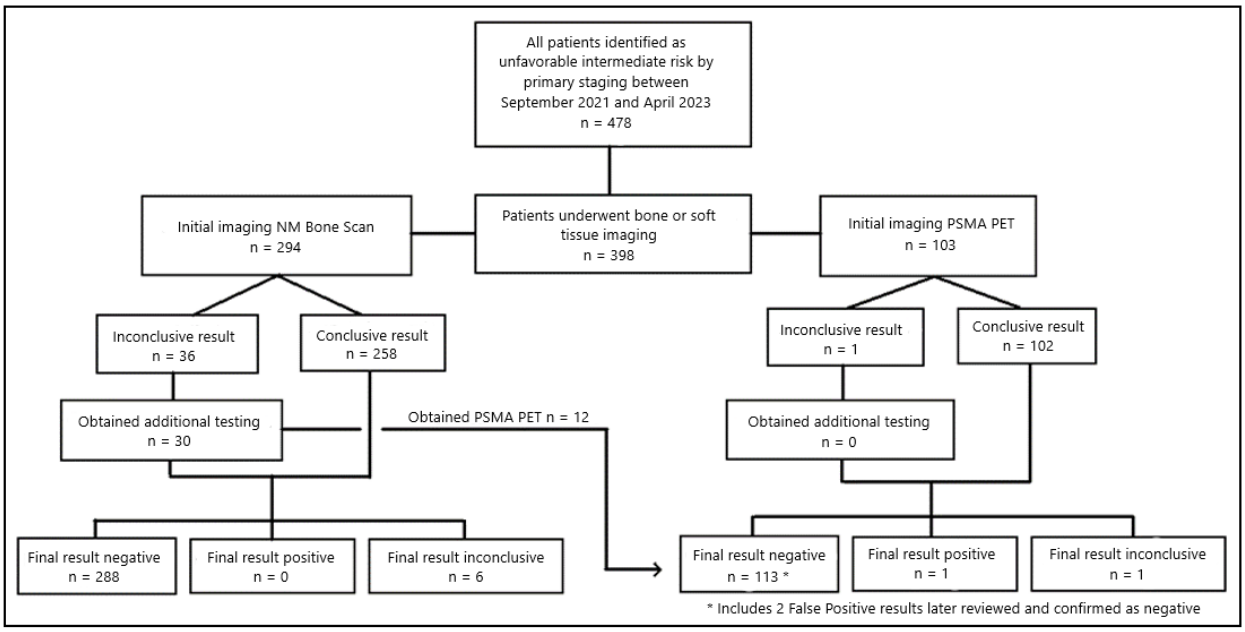


Figure 1: Flowchart of patient selection and data analysis

Descriptive analysis was performed, and data subdivided between patients who initially underwent NM Bone scan vs PSMA PET. Inconclusive test results were further reviewed for

additional confirmatory testing. Scan results that could not be validated were excluded from analysis. Positive predictive value, number needed to image, number needed to harm, and specificity were calculated for each cohort, as well as the total set of imaging obtained.

## Results

Of 294 NM Bone scans 36 were inconclusive (10.04%) prompting 30 patients to obtain additional testing. None were determined to correlate with positive metastatic soft tissue disease for a PPV of 0%. 1 in every 9.6 patients could be considered to have been harmed by this testing.

Of 114 PSMA PET scans 1 was determined to correlate with positive metastatic soft tissue disease (0.88%), with a PPV of 33.3%. 1 in every 57 patients could be considered to have been harmed by this testing.

| Imaging type | Positive Result | | Negative Result | | PPV | Specificity | Number Needed to Image * | Number Needed to Harm ** |
|---|---|---|---|---|---|---|---|---|
| | True Positive | False Negative | True Negative | False Positive | | | | |
| *NM Bone Scan* | 0 | 0 | 258 | 30 | 0 | 0.896 | N/A | 9.6 |
| *PSMA Pet Scan* | 1 | 0 | 111 | 2 | 0.33 | 0.982 | 114 | 57 |
| *Combined Imaging* | 1 | 0 | 369 | 32 | 0.03 | 0.920 | 402 | 12.6 |

Figure 2: Results and analysis by imaging type

** Reflects number of scans necessary to obtain a single true positive result*

*** Reflects number of scans necessary to obtain either a false positive result or a result requiring additional intervention*

## Conclusions

NM Bone scans and PSMA PET scans appear to be of extremely low utility in patients with unfavorable intermediate risk CaP, causing more harm to patients than benefit, requiring 402 scans for a single positive finding. The NCCN guidelines recommending bone and soft tissue imaging for all patients with unfavorable intermediate risk CaP should be reconsidered.